

# Orthopedics of rapid maxillary expansion with a face mask in a patient with unilateral cleft lip and palate: A case report

Ortopedia de la expansión maxilar rápida con mascarilla facial en un paciente con labio y paladar hendido unilateral: Informe de un caso

Miriam V. Lima-Illescas | Karla Saldaña | Jhomille Garzón |  
Melissa Berrezueta

**Recibido:** 30 de septiembre de 2023


**Aceptado:** 01 de diciembre de 2023

**DOI:** <https://doi.org/10.18272/esferas.v5i.3114>

**Cómo citar:** Lima-Illescas, M., Saldaña, K., Garzón, J. y Berrezueta, M. (2024).

Orthopedics of rapid maxillary expansion with a face mask in a patient with unilateral cleft lip and palate:

A case report. *Esferas*, 5, pp. 39-52. <https://doi.org/10.18272/esferas.v5i.3114>



Miriam V. Lima-Illescas  
Universidad Católica de Cuenca  
Cuenca 01010102, Ecuador  
[mimai@ucacue.edu.ec](mailto:mimai@ucacue.edu.ec)  
<https://orcid.org/0000-0001-6844-3826>

Karla Dayanna Saldaña Cordero  
Universidad Católica de Cuenca  
Cuenca 01010102, Ecuador  
[karladaya1524@hotmail.com](mailto:karladaya1524@hotmail.com)  
<https://orcid.org/0009-0004-8651-333X>

Jhomille Abigail Garzón Estrella  
Universidad Católica de Cuenca  
Cuenca 01010102, Ecuador  
[jhomilee.garzon@est.ucacue.edu.ec](mailto:jhomilee.garzon@est.ucacue.edu.ec)  
<https://orcid.org/0009-0001-9714-4320>

Melissa Elizabeth Berrezueta Pérez  
Universidad Católica de Cuenca  
Cuenca 01010102, Ecuador  
[melissa.berrezueta@est.ucacue.edu.ec](mailto:melissa.berrezueta@est.ucacue.edu.ec)  
<https://orcid.org/0009-0004-5839-8004>

## Abstract

Cleft lip and palate is a congenital malformation that is generally associated with class III skeletal malocclusion. This is due to the lack of union of the nasopalatine processes that generate craniofacial and dentoalveolar anomalies. However, the management of this class III malocclusion is through early orthopedic treatment. The purpose of this case report is to describe the orthopedic changes of rapid maxillary expansion using a facemask in a patient with non-syndromic unilateral cleft lip and palate. This is a case report of an 8-year-old boy with class III malocclusion due to maxillary retrusion and left posterior crossbite. A Hyrax intraoral rapid maxillary expansion appliance was used to correct the transverse deficiency of the anterior sector, and after that, the Petit facial mask was placed, correcting at the sagittal level, which could be used for 11 months, thus achieving significant dental-skeletal changes in a short time due to the collaboration of the parents and the age of the patient. Early treatment of patients with unilateral cleft lip and palate had optimal dentoskeletal outcomes. This improved the posterior transverse relationship as well as in the sagittal plane, due to the advancement of the upper jaw, this was successful thanks to the collaboration of the patient, family members and the young age of the patient.

**Keywords:** cleft lip, cleft palate, malocclusion, Angle class III, therapeutics, dentistry

## Resumen

El labio y paladar hendido es una malformación congénita que generalmente se asocia a una maloclusión esquelética de Clase III. Esto se debe a la falta de unión de los procesos nasopalatinos que generan anomalías craneofaciales y dentoalveolares. Sin embargo, el tratamiento de esta maloclusión de Clase III pasa por un tratamiento ortopédico precoz. El propósito de este caso clínico fue describir los cambios ortopédicos de la expansión rápida del maxilar utilizando una máscara facial en un paciente con labio y paladar hendido unilateral no sindrómico. Se trata de un paciente de 8 años con maloclusión de Clase III debido a retrusión maxilar y mordida cruzada posterior izquierda. Se utilizó un aparato de expansión rápida maxilar intraoral Hyrax para corregir la deficiencia transversal y posteriormente se colocó la máscara facial Pettit, corrigiendo a nivel sagital durante 11 meses, consiguiendo así cambios dentoesqueléticos significativos en poco tiempo debido a la colaboración de los padres y a la edad del paciente. El tratamiento precoz de los pacientes con labio y paladar hendido unilateral tuvo resultados dentoesqueléticos óptimos. Esto mejoró la relación transversal posterior, así como en el plano sagital, debido al avance del maxilar superior, gracias a la colaboración del paciente, familiares y la corta edad del paciente.

**Palabras clave:** labio hendido, fisura del paladar, maloclusión de Angle Clase III, terapéutica, odontología

## Introduction

Cleft lip and palate are congenital craniofacial malformations, which have consequences such as: physical, emotional, aesthetic, psychological, auditory, phonetic and dentoskeletal problems in which malocclusions, agenesis, crowding, supernumerary teeth and eruption alterations can occur (Lopera et al., 2010, p. 49). Patients with this pathology undergo several surgical interventions and suffer a reduction of the anterosuperior bone arch, which is why they, generally suffer from skeletal class III malocclusion (Conde, 2017, p. 23).

Skeletal class III malocclusion is an anomalous maxillo-mandibular relationship, in which the lower arch occludes mesially in relation to the upper arch, it's characterized by maxillary retrognathism, mandibular prognathism; while the upper incisors are proclined and the mandibular incisors are retroinclined (Rodríguez et al., 2020, p. 207; Vallejo et al., 2022, p. 2).

Other anomalies include transverse problems that can present themselves at very early ages. However, through rapid expansion of the maxilla, separation of the midpalatal suture is produced, thus increasing the transverse distance of the upper arch, achieving a separation of 0.2 to 0.5 mm per day in patients with skeletal growth; commonly used in cross bites, maxillary retrusion, upper crowding, and others (Conde, 2017, p. 24; Zambonino et al., 2018, p. 37; Vallejo et al., 2020, p. 3).

The cause of this malformation is multifactorial, involving genetic factors that may be due to heredity or chromosomal alterations, and environmental factors as viral infections, radiation, advanced age of the mother, or malnutrition of the pregnant mother (Barhoum et al., 2016, p. 31). The worldwide prevalence mentions a frequency of cleft lip and palate of 14:10 000 Asian births, followed by 10:10 000 white births and lastly of 4:10 000 African American births (Cisneros et al., 2019, p. 77).

There are two types of palatal fissures: primary palatal fissure involving the lip and premaxilla, and secondary palatal fissure involving the hard, soft palate posterior to the incisive foramen (Conde, 2017).

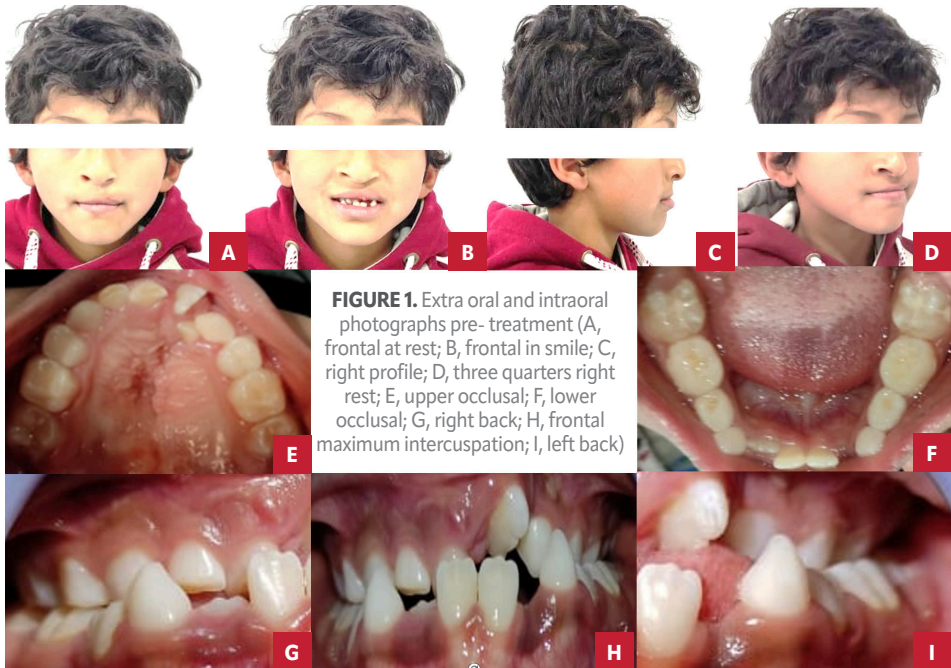
Rapid maxillary expansion appliances such as the Hyrax consist of a screw in the center and two bands on the sides that are adapted to the first premolars and first molars. These are made of stainless steel wire and are tooth-supported (Pérez et al., 2019, p. 25; Ameneiros et al., 2021, p. 3).

The purpose of this case report is to describe the orthopedic changes of rapid maxillary expansion using a facemask in a patient with non-syndromic unilateral cleft lip and palate.

## Case description

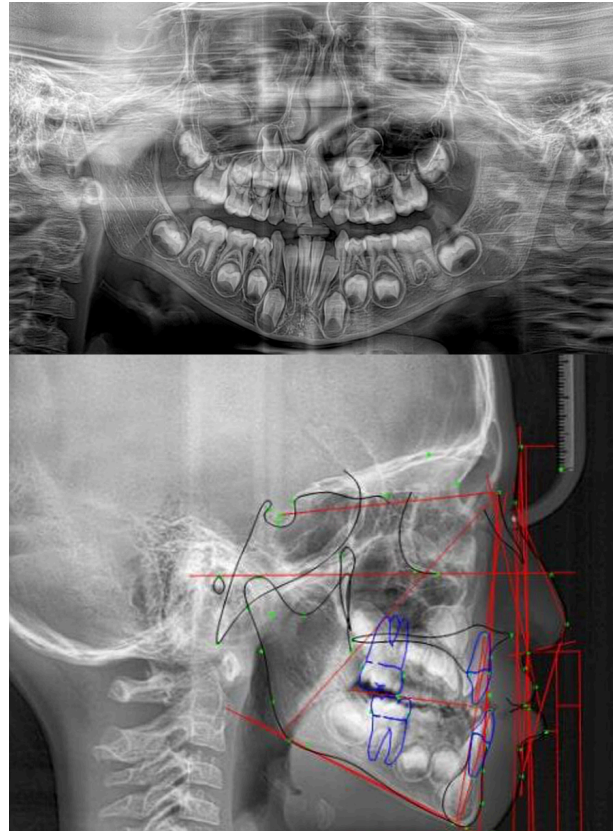
An 8-year-old male patient was attended at the Cleft Lip and Palate clinic of the Universidad Católica de Cuenca, with a main complaint: "I cannot speak clearly". In his personal history, he presented sequels of a non-syndromic unilateral cleft lip and palate. The representative reported two previous surgeries; the first was cheiloplasty at 5 months of age and palatorrhaphy at 9 months of age, absence of dental history and in the medical history there are no hereditary reports of this anomaly in the family. At a functional level, he presented alteration in phonation and hypernasality. The pre-treatment facial analysis showed a brachyfacial biotype, asymmetric thirds, lateralized base of the left nasal ala, high cupid's bow, asymmetric bases of the nostrils, mid-facial plane incongruent with the upper dental midline, sequels of the left cleft lip and palate, straight profile, prominent upper lip, sunken lower lip and normal mandible.

The intraoral examination revealed first phase mixed dentition, an oval shaped upper arch, a cleft palate scar, 1.1 in mesioversion, 6.2 in palatoversion and absence of 2.2, in the mayoral analysis he presented micrognathism at the level of the first molars (42 mm), the tooth-bone discrepancy was negative (-5 mm); meanwhile, the lower arch was also oval shaped, 4.2 mideruption and 3.2 absent, the tooth-bone discrepancy was negative (-1 mm). In the sagittal analysis of the occluded arches, the overjet was -2 mm, bilateral canine mesiocclusion, class III right molar relationship and class I left molar; in the vertical relation, the overbite was 2 mm, and in the transversal plane there was a coincidence of dental midlines and crossbite throughout the left posterior section (Figure 1).



The orthopantomography showed adequate alveolar support, permanent teeth in different stages of formation, agenesis of tooth 2.2, deviation of the nasal septum to the right side, and left nasoalveolo-palatal fissure. The cephalometric analysis of the lateral skull X-ray was performed using the Dolphin Imaging v11.0 program, which confirmed the skeletal class III malocclusion and a mesofacial biotype. After consultation with the speech therapist, it was decided to first perform orthopedic treatment (Figure 2).

Measurements	Norm	Pretreatment
S-N	71 mm ±2	60.8 mm
Go-Me	71 mm ±3	61.9 mm
Ba.N/Pt.Gn	90°±3	88.0°
FH/N.Po	87°±3	86.4°
FH/Go.Me	47°±4	27.6°
Dc.XiXi.Pm	26°±3	30.8°
SNA	80°±5	81°
S.N/P. Palatino	8.5°	4°
FH/N.A	90°±3	86.4°
SNB	78°±5	80.7°
S.N/Go.Gn	32°	32.4°
ANB	2°	0.2°
N.Po/A	2±2 mm	0.1 mm
Xi.ENA/Xi.Pm	47°±3	43.8
Is/P. palatino	110°	79.5°
Is/A.Po	28°	-5.4°
Is/S.N	102°±2	75.4°
Is/A.Po	4 mm	-3.5 mm
IMPA	90°±3	78.3°
li/A.Po	22°±4	12.2°
li/A.po	1-2 mm	1.0 mm
Is-II	130°±6	173.1°
Plano E	1 mm	2.9 mm



**FIGURE 2.** Panoramic X-ray and pre-treatment cephalometric tracing

## Treatment objectives

The objectives of the treatment were based on the clinical diagnosis, model study and cephalometric study, for which reason it was planned:

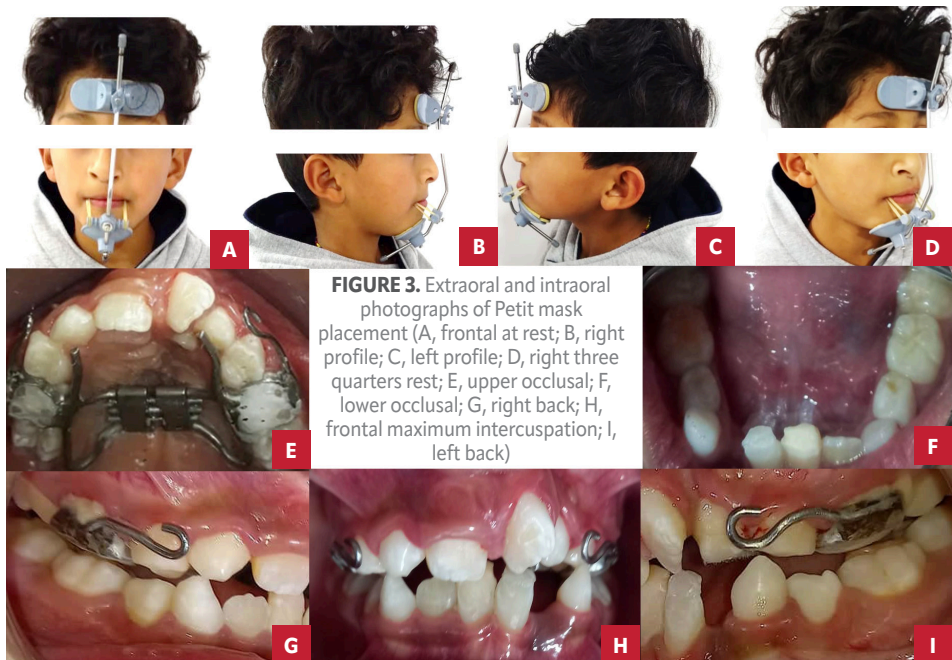
- Transversely expand the upper jaw
- Protract the maxilla
- Achieve facial and skeletal harmony
- Improve the tooth-bone discrepancy
- Improve the patient's self-esteem

## Treatment plan

The treatment began with the placement of a Hyrax breaker featuring two bands on the first temporary molars and stainless-steel hooks welded from the bands to the canines and later a Petit mask was used with 1/2" 14 oz elastics.

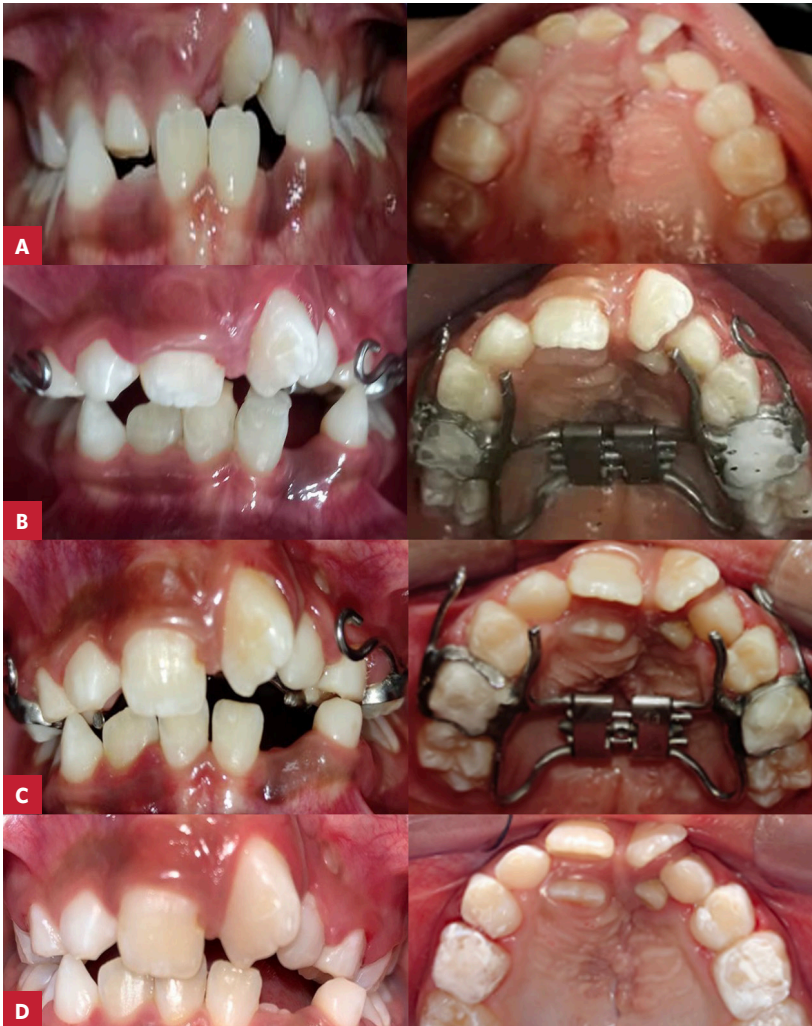## Treatment progress

The intraoral orthopedic Hyrax appliance was used with an 11mm screw and its activation protocol was to achieve rapid maxillary expansion, 2/4 turns were performed daily for 5 days, resulting in an expansion of 2.5 mm approximately, then a Petit face mask was placed, the elastics were anchored from the hooks of the intraoral appliance to the horizontal stem of the mask with an inclination of approximately 35° below the occlusal plane and its use was minimum 12 hours a day.



After 4 months of using the Petit facial mask, anteroinferior resin lifts were placed for class III malocclusion to serve as a guide for the antagonist teeth, and the anterior bite was uncrossed (Figure 3).

The patient used the facial mask for 11 months, even during school activities, while sleeping, and only removed it for eating and playing, which is why important changes were observed in such a short period of time and the patient was referred to speech therapy and consultation with the maxillofacial surgeon. The patient was recommended to attend quarterly check-ups in the orthodontics area. (Figure 4)

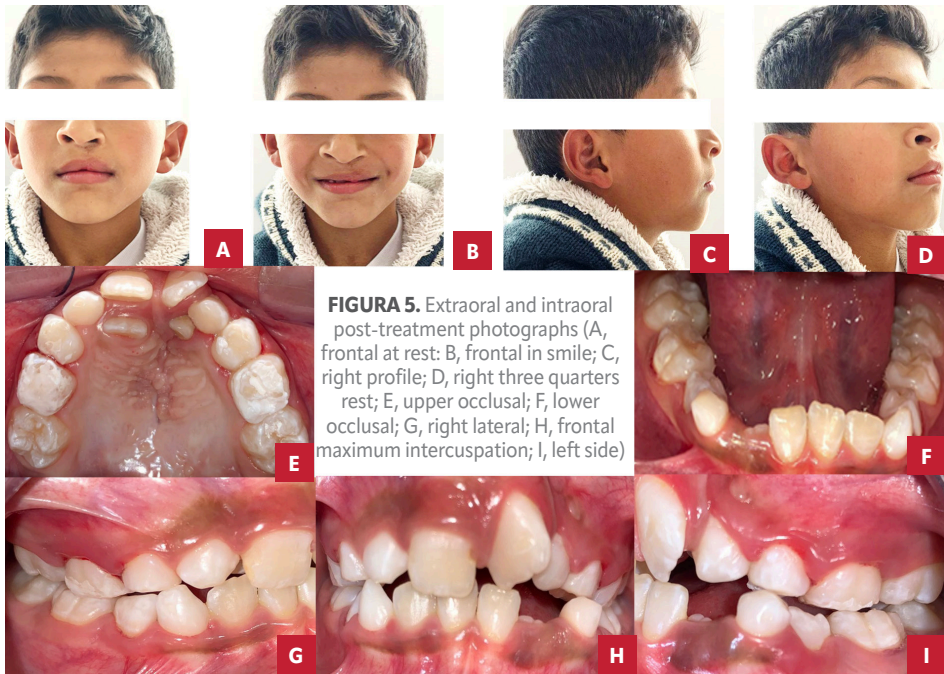


**FIGURE 4.** Intraoral occlusion and upper arch photographs of treatment progress (A, Pre-treatment; B, 4 months; C, 6 months; D, 11 months of treatment)



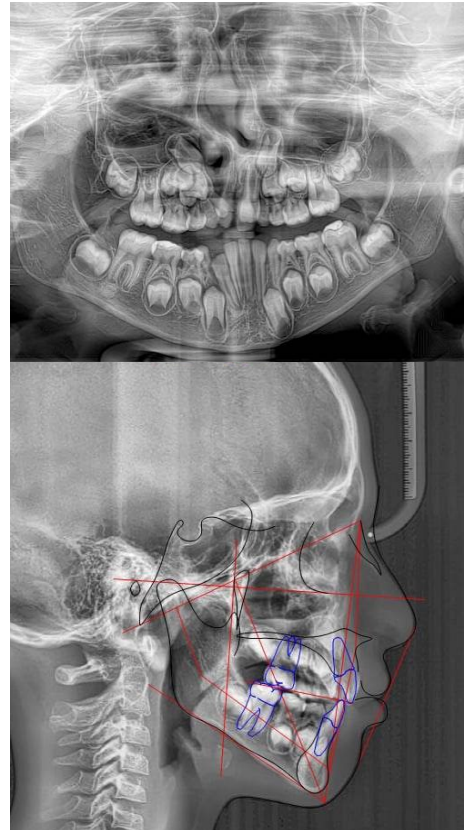
The post-treatment frontal facial analysis of the patient showed no significant changes (lateralized base of the left nasal ala, elevated cupid's bow, asymmetric bases of the nostrils). However, the facial profile was now evidently a convex profile, upper lip slightly sunken, normal mandible.

In the final intraoral examination, he presented a second phase mixed dentition, the upper and ovoid lower arches, cleft palate scar, 1.2 and 6.2 in palatoversion, in the final Mayoral analysis, the micrognathism was maintained at the level of the molars (42 mm), the tooth-bone discrepancy remained in the upper and lower arches. In the analysis of the arches in occlusion in the sagittal plane, the overjet was 1mm, right canine distocclusion and left canine mesiocclusion, bilateral class II molar relationship; in the vertical plane, the overbite was 2 mm, and in the transverse plane there was a coincidence of dental midlines (Figure 5).



In the final cephalometric analysis, skeletal changes of the upper jaw were observed when comparing the pre and post-treatment measurements, a skeletal class I was shown, there was a protraction of the upper jaw, the mandibular position was maintained, and there was a procumbence and protrusion of the upper incisor (Figure 6).

Measurements	Norm	Pretreatment	Posttreatment
S-N	71 mm ±2	60.8 mm	61.1 mm
Go-Me	71 mm ±3	61.9 mm	55.6 mm
Ba.N/Pt.Gn	90°±3	88.0°	86.4°
FH/N.Po	87°±3	86.4°	86.6°
FH/Go.Me	47°±4	27.6°	30.1°
Dc.XiXi.Pm	26°±3	30.8°	34.1°
SNA	80°±5	81°	84.0°
S.N/P. Palatino	8.5°	4°	4.8°
FH/N.A	90°±3	86.4°	91.6°
SNB	78°±5	80.7°	80°
S.N/Go.Gn	32°	32.4°	36.5°
ANB	2°	0.2°	4°
N.Po/A	2±2 mm	0.1 mm	4.0 mm
Xi.ENA/Xi.Pm	47°±3	43.8	43.8
Is/P. palatino	110°	79.5°	102.3°
Is/A.Po	28°	-5.4°	23.1°
Is/S.N	102°±2	75.4°	97.4°
Is/A.Po	4 mm	-3.5 mm	2.1 mm
IMPA	90°±3	78.3°	80.8°
li/A.Po	22°±4	12.2°	23.1°
li/A.po	1-2 mm	1.0 mm	- 0.8 mm
Is-II	130°±6	173.1°	144.1°
Plano E	1 mm	2.9 mm	2.9 mm



## Discussion

Cleft lip and palate is the most common congenital malformation in the facial region, its etiology is multifactorial, it can be genetic by inheritance or by chromosomal alterations, and environmental factors during pregnancy, the most common being viral infections, chemical agents, radiation, malnutrition or age of the mother; having a lower frequency on the right side than the left (Conde, 2017, p. 24; Barhoum et al., 2016, p. 31; Cisneros et al., 2019, p. 77) stated that non-syndromic malformations represent 70 % of cases and a malformation that is associated with syndromes represents 30 % of cases.

Class III skeletal malocclusions can be produced by maxillary retrusion in pediatric patients with cleft lip and palate, as a result of various surgeries (cheiloplasty, palatoplasty) leading to transverse and sagittal alterations of the maxilla (García et al., 2019, p. 250). In a research study conducted by Durón et al. (2017), it was found that due to the maxillary surgery taken place, the nasal septum will not be able to grow adequately, keeping it short, deficient and thus causing depression of the middle third of the face (p. 90).

In the case described, the Hyrax circuit breaker was used in combination with the face mask, since it is considered a first-choice therapeutic resource in patients who are still growing and with class III malocclusion (Delgado et al., 2019, p. 278; Espinoza et al., 2018, p. 50; Ramos et al., 2016, p. 65). When the rapid expansion of the maxilla happened, it also corrected the posterior cross bite on the left side, showing changes in the transverse direction; and in the sagittal plane, a maxillary advancement of 3.9 mm was demonstrated according to Ricketts' facial convexity (initial convexity +0.1 mm; final convexity +4 mm) taking into account that the appropriate age is before 12 years of age for the treatment to be effective (Mendoza et al., 2014, p. 113; Pérez et al., 2020, p. 186). Meanwhile Hidalgo et al. (2018), mentions that the age limit for orthopedic disjunction is 15-years-old, since transverse discrepancies of less than 5 mm can be corrected with orthopedic expansion and transverse discrepancies in patients with skeletal maturity of more than 5 mm require surgical expansion (p. 27).

The patient showed evident and satisfactory clinical changes, due to the fact that the patient and family members were very collaborative during the use of Petit's face mask for 11 months and a minimum of 16 hours a day; Jia et al. (2018), demonstrated that there were greater skeletal changes within a time span of 9.2 months and with the use of the facial mask for 12 hours (p. 621).

## Conclusion

Early treatment of patients with unilateral cleft lip and palate had optimal dentoskeletal outcomes, in this case report the orthopedic treatment was a rapid expansion of the maxilla along with the face mask, which led to an improvement in the posterior transverse relationship, as well as in the sagittal plane, due to the advancement of the upper jaw, this was successful thanks to the collaboration of the patient, family members and the young age of the patient.

## Consent for Publication

This case report was performed at the Universidad Católica de Cuenca, was funded by project Multidisciplinary Treatment of Patients with Cleft Lip and Palate (code: VCS-2021-01-005). Informed consent was obtained from the parents for publication.

## Authors' contributions

All authors contributed equally to this article.

## **Acknowledgments**

Authors would like to thank Universidad Católica de Cuenca for providing the resources for care at Cleft Lip and Palate Clinic.

## **Conflict of Interest**

The authors declare that there is no conflict of interest.

## References

- Ameneiros, O., Soto, A., & Cruz, D. (2021). Expansión ortopédica del maxilar. Disyunción rápida. *Investigaciones Médicoquirúrgicas*, 13(1), 1-14. <https://revcimeq.sld.cu/index.php/imq/article/view/720>
- Barhoum, H., León, M., & Benjumea, N. (2016). Paciente con labio y paladar fisurado bilateral, mordida cruzada anterior y con severa comprensión maxilar tratado con ortodoncia temprana, Hyrax y cirugía ortognática monomaxilar. Reporte de caso. *Revista de Estomatología de salud*, 24(1), 30-36. <https://hdl.handle.net/10893/9917>
- Cisneros, C., Sotomayor, G., & Bernal, M. (2019). Importancia del manejo interdisciplinario de pacientes con Fisuras Labiopalatinas y Anemia de Blackfan Diamond. Reporte de caso: seguimiento a 2 años. *Revista de Odontopediatría Latinoamericana*, 9(1), 75-89. <https://doi.org/10.47990/alop.v9i1.169>
- Conde, D. (2017). Expansión rápida maxilar en pacientes hendiduras labio palatinas: reporte de caso. *Journal Odontológico Colegial*, 10 (20), 22-32. <https://revistas.unicoc.edu.co/index.php/joc/article/view/359>
- Delgado, C., Rosenberg, F., Keith, F., & Scheu, J. (2019). Expansión rápida del maxilar superior y su impacto a nivel de la vía aérea superior: revisión bibliográfica. *Odontología Sanmarquina*, 22(4), 277-282. <https://doi.org/10.15381/os.v22i4.17049>
- Durón, R., Granados, M., Canseco, L., Cuairán, V., & Canseco, J. Ortopedia prequirúrgica en pacientes de labio y paladar hendido unilateral: presentación de casos clínicos. *Revista Mexicana de Ortodoncia*, 5(2), 89-99. <https://www.medigraphic.com/cgi-bin/new/resumen.cgi?IDARTICULO=71879>
- Espinoza, S., Gurrola, B., & Casasa, A. (2018). Manejo del paciente con apiñamiento severo y mordida cruzada posterior bilateral con expansor maxilar tipo Hyrax. *Odontología vital*, 2(29), 49-58. <https://doi.org/10.59334/ROV.v2i29.149>
- García, A., Guzmán, I., López, J., Mosqueda, P., Pérez, C., Medina, V., Solís, M., & Rodríguez, M. (2019). Paciente con secuela de labio y paladar hendido. Tratamiento ortodóncico y quirúrgico. *Revista Mexicana de Ortodoncia*, 7(4), 247-257. <https://www.medigraphic.com/cgi-bin/new/resumen.cgi?IDARTICULO=102026>
- Hidalgo, V., Solano, B., & Solano, E. (2018). Indicaciones de las distintas técnicas de expansión rápida del paladar quirúrgicamente asistida y comparativa de la estabilidad. *Revista Española de Cirugía Oral y Maxilofacial*, 40(1), 27-32. <https://doi.org/10.1016/j.maxilo.2017.01.002>
- Jia, H., Li, W., & Lin, J. (2008). Maxillary protraction effects on anterior crossbites. *Angle Orthodontist*, 78(4): 617-623. [https://doi.org/10.2319/0003-3219\(2008\)078\[0617:MPEOA C\]2.0.CO;2](https://doi.org/10.2319/0003-3219(2008)078[0617:MPEOA C]2.0.CO;2)
- Lopera, A., & Botero, P. (2010). Tratamiento para la corrección de mordidas cruzadas posteriores bilaterales. *CES Odontología*, 23(1), 49-58. <https://revistas.ces.edu.co/index.php/odontologia/article/view/1210>

- Mendoza, K., González, M., & Mora, I. (2014). Efectividad de la máscara facial y un aparato intraoral en pacientes con labio y paladar hendido: una revisión sistemática. *Universitas Odontológica*, 33(70), 107-119. <https://revistas.javeriana.edu.co/index.php/revUnivOdontologica/article/view/6003>
- Pérez, A., Gallegos, F., Hernández, M., Torres, P., Cuevas, P., & Fierro, C. (2020). Riesgos asociados al uso de expansión rápida del maxilar. *Avances en Odontoestomatología*, 36(1), 21-25. [http://scielo.isciii.es/scielo.php?script=sci\\_arttext&pid=S0213-12852020000100003&lng=es](http://scielo.isciii.es/scielo.php?script=sci_arttext&pid=S0213-12852020000100003&lng=es)
- Pérez, E., Iturbide, J., Cavazos, E., Orúe, A., Aguilera, J., & Torres, P. (2019). Cambios cefalométricos de la vía aérea superior posterior a expansión rápida palatina con y sin máscara facial. *Revista Mexicana de Ortodoncia*, 7(4), 183-189. <https://www.medigraphic.com/cgi-bin/new/resumen.cgi?IDARTICULO=102020>
- Ramos, R., & Valencia, M. (2016). Tratamiento ortodóntico con disyuntor Hyrax en pacientes dolicofacial con ausencias típicas: Reporte de caso. *Odontología Activa*, 1(2), 61-66. <https://doi.org/10.31984/oactiva.v1i2.148>
- Rodríguez, L., Delgado, L., & Rodríguez, M. (2020). Tratamiento de la hipoplasia anteroposterior maxilar. *Medicentro Electrónica*, 24(1), 207-215. [http://scielo.sld.cu/scielo.php?script=sci\\_arttext&pid=S1029-30432020000100207&lng=es](http://scielo.sld.cu/scielo.php?script=sci_arttext&pid=S1029-30432020000100207&lng=es)
- Vallejo, L., Vallejo, K., Collantes, J., & Rockenbach, C. (2022). Expansión rápida del maxilar: una revisión de literatura. *Research, Society and Development*, 11(9), 1-7. <https://doi.org/10.33448/rsd-v11i9.30492>
- Vallejo, L., Collantes, J., Rockenbach, M., Vallejo, K., & Vallejo, D. (2020). Eficacia de los aparatos de expansión rápida maxilar Hyrax y Hass. *Journal of Multidisciplinary Dentistry*, 10(2), 112-9. <https://doi.org/10.33448/rsd-v11i9.30492>
- Zambonino, P., Gurrola, B., & Casasa, A. (2018). Expansión Maxilar en la corrección de mordida cruzada posterior derecha. *Odontología Activa*, 3(3), 37-42. <https://doi.org/10.31984/oactiva.v3i3.279>